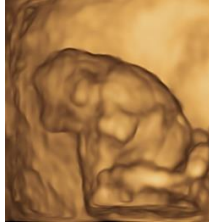


Videos of ultrasonography of fetal abnormalities

(I) First trimester

Exencephaly



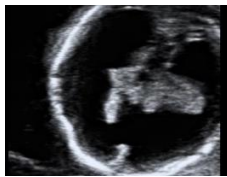Creator: KY Leung, EC, AFSUMB

Duration: 0:21

This clip shows the absence of the cranial vault, and the protrusion of the uncovered brain tissue out of the cranial cavity on two-dimensional and three-dimensional ultrasound examinations.

Published on 23 January 2021, used with permission

Holoprocencephaly



Creator: KY Leung, EC, AFSUMB

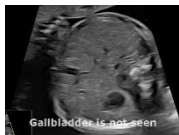Duration: 0:16

This clip shows absence of the interhemispheric fissure anteriorly, and fused thalami.

Published on 23 January 2021, used with permission

(II) Mid-trimester

Non-visualization of the fetal gallbladder



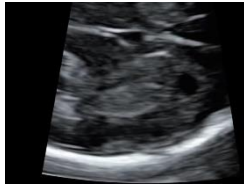Creator: KY Leung, EC, AFSUMB

Duration: 0:21

This clip shows the fetal gallbladder is not visualized in the transverse and coronal view of two-dimensional ultrasound examinations as well three-dimensional multi-slice view.

Published on 23 January 2021, used with permission

Agensis of corpus callosum



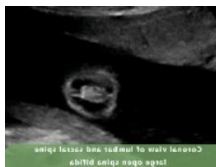
Creator: KY Leung, EC, AFSUMB

Duration: 1:20

This clip shows that (a) cavum septi pellucidi is not seen, the interhemisphere fissure is widened, an interhemispheric cyst is seen, and the frontal horn is further away than normal from the midline in the transverse view, and (b) corpus callosum is not seen and the course of the pericallosum artery is abnormal in the sagittal view.

Published on 23 January 2021, used with permission

Open spina bifida



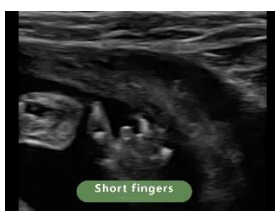Creator: KY Leung, EC, AFSUMB

Duration: 2:33

This clip shows the coronal view of the fetal lumbar and sacral spine. A large cystic mass overlying the spine is indicative of open spina bifida

Published on 23 January 2021, used with permission

Hand abnormalities



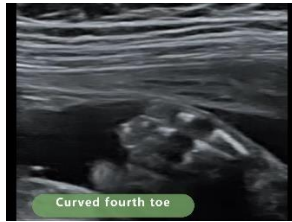Creator: KY Leung, EC, AFSUMB

Duration: 1:01

This clip shows five hand-abnormalities including club hand, deviated thumb, short fingers, pre-axial polydactyly, and abducted thumb

Published on 23 January 2021, used with permission

Foot abnormalities



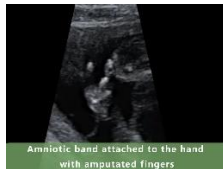Creator: KY Leung, EC, AFSUMB

Duration: 0:39

This clip shows three foot-abnormalities including saddle gap, curved fifth toe and curved fourth toe.

Published on 23 January 2021, used with permission

Amniotic band sequence



Creator: KY Leung, EC, AFSUMB

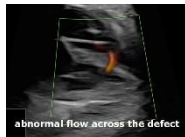Duration: 0:53

This clip shows amniotic band sequence with a band attached to the thorax, and to a hand with amputated fingers.

Published on 23 January 2021, used with permission

(III) Third trimester

Ventricular septal defect



Creator: KY Leung, EC, AFSUMB

Duration: 0:21

This clip shows a small ventricular septal defect which is demonstrated by an abnormal flow across the interventricular septum on color Doppler examination.

Published on 23 January 2021, used with permission